

CASE SPOTLIGHT | Genicular Artery Embolization for Chronic Pain After Total Knee Arthroplasty

By Keerthi Prasad, MD

PATIENT PRESENTATION

A man in his mid 70s presented with chronic, dull, aching pain in his left knee. The pain had been progressively worsening over the last 2 years after a left total knee arthroplasty (TKA). He denied any new trauma and had completed physical therapy without relief. A recent x-ray was unremarkable, showing no signs of hardware loosening or other structural issues.

The patient's initial pain assessment revealed a visual analog scale (VAS) score of 7/10 and an Oxford Knee Score of 15, indicating severe pain and poor function. Physical examination of the left knee showed a healed TKA scar, normal muscle tone, and no focal tenderness. The left knee appeared larger than the right. His range of motion was limited, with flexion at 90°. The diagnosis was chronic pain after TKA.

PROCEDURAL OVERVIEW

The genicular artery embolization (GAE) procedure was performed via a left dorsalis pedis artery approach, where a 4-F, 10-cm sheath was placed under ultrasound guidance. A 4-F angled hydrophilic catheter and a 0.035-inch-diameter guidewire were used to navigate to the popliteal artery. An angiogram at this level demonstrated a prominent superior lateral genicular artery (SLGA) (Figure 1A).

Craniocaudal and ipsilateral angulation were utilized to achieve optimal visualization of the SLGA's origin. The origin of the artery was engaged with the catheter.

A 2.5-F, 110-cm Cantata® microcatheter (Cook Medical) was then used to selectively cannulate the SLGA. A microwire guide was not needed. A subsequent angiogram showed a prominent blush consistent with extensive hypervascularity and synovial hypertrophy (Figure 1B).

Embolization was performed with a dilute suspension of 100-µm beads, delivered in 0.2-mL aliquots for a total volume of 1.2 mL (Figure 1C). On completion, the devices were removed uneventfully, and hemostasis was achieved with ultrasound-assisted compression. Completion angiography demonstrated resolution of the abnormal blush (Figure 1D).

OUTCOME AND FOLLOW-UP

The patient reported significant pain improvement as early as day 3 postprocedure. At 14-day follow-up, his pain remained significantly improved, with his VAS score dropping to 2/10 and his Oxford Knee Score increasing to 27. This clinical improvement was maintained at 3-month follow-up, with a VAS score of 1/10 and an Oxford Knee Score of 27. The patient also demonstrated significant improvement in his range of motion.

PHYSICIAN DISCUSSION

This case highlights the effectiveness of GAE in a patient with chronic post-TKA pain. Post-TKA patients often present with chronic pain but typically lack focal tenderness, making diagnosis challenging. Limited options are typically available for this population. The angiographic finding of hypervascularity in this patient's SLGA was a key indicator in this case and consistent with postsurgical synovial hypertrophy.

The Cantata microcatheter was particularly useful in this case due to its ability to maintain position and its shorter length, allowing for comfortable ergonomics. Its soft tip also facilitated distal positioning, beyond nontargeted branches and without concern for perforation. In our experience, these cases often require a larger total volume of embolic material than embolization for osteoarthritis. The 2.5-F microcatheter lumen is very well suited for this purpose. The significant and sustained improvement in pain and function demonstrates that GAE can be a valuable treatment option for patients experiencing persistent pain after TKA. ■

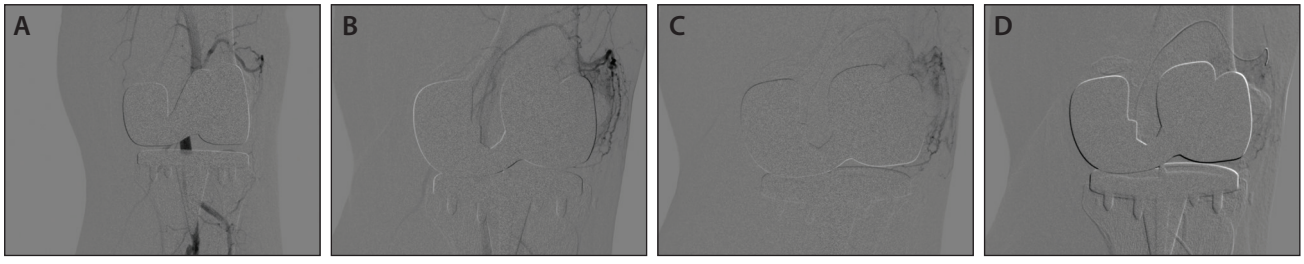

Figure 1. Angiography confirming a prominent SLGA (A). Angiography showing prominent blush, consistent with extensive hypervascularity and synovial hypertrophy (B). Angiography demonstrating embolization of the target lesion with 100-µm beads (C). Completion angiography prior to device removal (D).

AI-WF611800-EN-F